



Foot & Practice

A foot health message from
Balanced Podiatry

Cancers affecting the feet



The main types of cancers that develop in the feet are skin cancers, bone cancers and soft-tissue tumours, with skin cancer being the most prevalent. The hole in the ozone layer means that Australians experience increased exposure to ultraviolet radiation compared to people in other parts of the world. As a result, the incidence of the most dangerous form of skin cancer — melanoma — is higher here.

Other cancers that can occur in the feet include bone and soft tissue sarcomas and metastatic cancers. Although skin cancers account for the majority of cancers in the feet. However, as a result of the other forms of cancer being quite rare in podiatric patients there are rather high levels of incorrect or delayed diagnosis for these conditions, resulting in incorrect first-line treatment for patients.

The main types of bone and soft tissue tumours affecting podiatric patients include chondrosarcomas, osteosarcomas, Ewing's sarcoma and synovial sarcomas. These conditions can be mistaken for sports injuries or conditions such as rheumatoid arthritis or osteomyelitis, depending on the specific condition.

Metastatic cancer can also develop in the feet, although this is rare due to the amount of time required for metastases to reach the lower extremities. When they do occur, metastases usually result from tumours originating in the subdiaphragmatic organs. It is unlikely for a primary tumour to remain undiagnosed when metastases are found in the lower extremities, and treatment will usually follow protocols for end-stage disease.

Melanoma in podiatric patients

Skin cancer is the main form of cancer affecting the feet, of which melanoma is the most dangerous. In podiatric patients, melanoma

usually appears between the toes, on or around the nail bed and on the soles of the feet.

Diagnosis

The ABCDEs of melanoma are important for quick diagnosis and early treatment:

A: Asymmetrical. Healthy moles are perfectly symmetrical; an asymmetrical mole can signify abnormal cell growth that may or may not be cancerous.

B: Borders. The borders of a mole with healthy cells will be even and distinct. On a mole with abnormal cells the border will be ragged or uneven.

C: Colour. Healthy moles will appear uniform in colour. In melanoma, the colour of a mole is unevenly distributed or has a multicoloured hue.

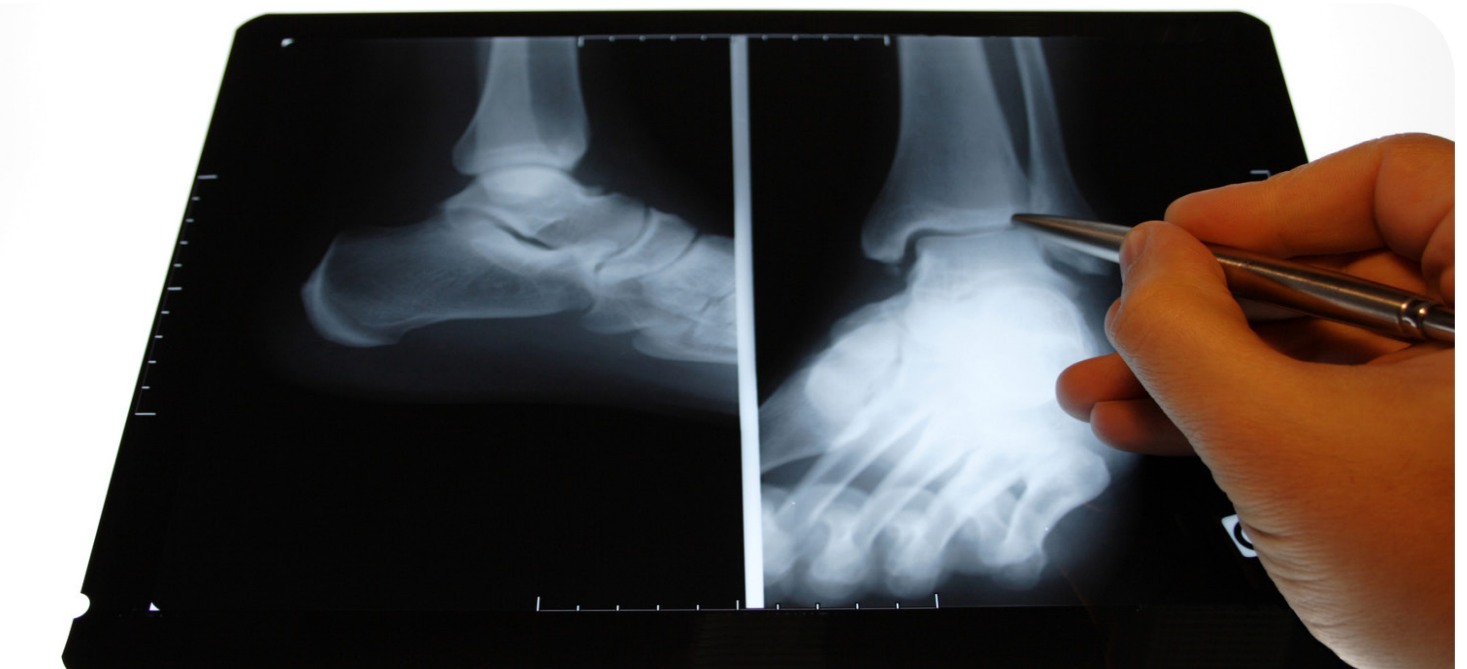
D: Diameter. Small moles have usually not grown enough for the amount of cell division required for melanoma to develop, so the larger the mole, the higher the risk of a positive diagnosis for melanoma. If the mole is larger than 6 mm in diameter a biopsy should be taken.

E: Evolving. Changing shape and size of a mole is indicative of abnormal cell division and potential malignant growth.

Additional risk factors for melanoma include changes to a mole or growth in the form of a rash, seeping blood or pus, and itching, which can all indicate changes to cells growth.

Treatment

The mole should be biopsied to determine disease stage and the best course of treatment for the patient. Following positive diagnosis for melanoma, treatment will vary by stage starting with removal of the mole and a further biopsy to test for the spread of disease to lymph nodes. If the cancer has spread, surgical options will be considered alongside the health and age of the patient to ensure best outcomes. Amputation may be a consideration for podiatric patients to ensure the removal of all malignant cells before the onset of metastasis. Oral or intravenous chemotherapy can be an effective therapy both in isolation and alongside surgical options. Radiation has been shown to be effective for metastatic melanoma. Biological therapies are effective on large melanomas and those that have spread to other areas of the skin. Targeted gene therapy is showing the most promise for the treatment of melanoma, with Australian approval for the administration of Vemurafenib providing hope for many patients.



Balanced Podiatry
Airlie Waller

175 Main South Rd
Yankalilla
5203

Ph-0428103494

A proud member of the Australian Podiatry Association (SA)